

# MIGS UPDATE: PRESENT AND FUTURE

The popularity of this safe and effective approach to glaucoma surgery will continue to grow as more options become available.

BY MICHAEL GREENWOOD, MD, AND JOHN BERDAHL, MD



The algorithm of glaucoma treatment has shifted dramatically, as a growing number of ophthalmologists have begun offering microinvasive glaucoma surgery (MIGS). The safety and effectiveness of these procedures have made

them an attractive option for early and moderate disease. As defined by Saheb and Ahmed, MIGS uses an ab interno microincision, produces minimal trauma, has a high safety profile, and is followed by rapid recovery.<sup>1</sup> This article reviews current MIGS options in the United States and previews the devices that may become available here in the future.

## CURRENTLY AVAILABLE

### Trabectome

Introduced in 2004, the Trabectome (NeoMedix) allows surgeons to perform a trabeculotomy via an internal approach. The device uses electrocautery to remove a strip of the trabecular meshwork and unroof Schlemm canal to allow aqueous to flow freely out of the eye. Surgeons can treat approximately 120° through a single incision, although larger treatment areas can be achieved with additional incisions.

### iStent

The iStent Trabecular Micro-Bypass Stent (Glaukos) was approved in 2012. This heparin-coated, nonferromagnetic titanium stent is shaped like a snorkel to facilitate implantation. At 1 mm in length, the iStent is currently the smallest FDA-approved device. It can be inserted at the time of cataract surgery through an incision of 1.5 mm or larger. The current FDA approval allows for the placement of just one iStent at the time of cataract surgery, but studies are underway on the implantation of additional stents as well as on the device's use in patients who are pseudophakic.

### Gonioscopy-Assisted Transluminal Trabeculotomy

Gonioscopy-assisted transluminal trabeculotomy is an ab interno procedure that involves creating a goniotomy,

“The algorithm of glaucoma treatment has shifted dramatically.”

cannulating Schlemm canal by passing a suture or a microcatheter through 360° of the canal, and retrieving the distal end of the suture or microcatheter, which the surgeon externalizes to complete the 360° trabeculotomy. Doing so removes any trabecular meshwork tissue that is contributing to outflow resistance.

### Ab Interno Canaloplasty

This procedure is similar to gonioscopy-assisted transluminal trabeculotomy in that a goniotomy is performed and Schlemm canal is cannulated by a microcatheter, but viscodilation is also performed. Once the microcatheter has passed through 360° of the canal, it is gently withdrawn along the same pathway, and viscoelastic is injected to dilate Schlemm canal and the collector channel system to restore aqueous flow of the distal drainage system.

## FUTURE DEVICES

### Trabecular Meshwork

It is easiest to classify the devices in development based on their anatomical placement. The second generation of the iStent, the iStent Inject (Glaukos), is currently in phase 3 FDA trials. Like its predecessor, the iStent Inject is also composed of titanium, but it is only 360 µm long. It also has a different shape. The stent has a narrow lumen and an apical head with four inlets through which aqueous can flow. A flange base

## MY EXPERIENCE WITH A GEL STENT



### By Keith Barton, MD, FRCP, FRCS

I have been working with the Xen45 gel stent (AqueSys; not FDA approved) for approximately 18 months and prior to that with its predecessor, the Xen 63. I have implanted more than 60 Xen45 devices. Unexpectedly, I have found it particularly beneficial in younger patients (25-60 years old) with marked IOP elevation who do not have significant optic nerve damage. From my perspective, the Xen comes closer to competing with trabeculectomy than other devices that I have used in the microinvasive glaucoma surgery category, though unlike the others, adjunctive mitomycin C is also required. I have seen IOPs of more than 50 mm Hg reduced

to the low teens with this device. Trabeculectomy still remains a more effective option for low-failure-risk patients with advanced glaucoma requiring low target pressures. I also use the Xen in cataract patients who have advanced glaucoma controlled by multiple medications. With the Xen, postoperative IOP spikes and hypotony are avoided, and the procedure is significantly less invasive than trabeculectomy.

### Keith Barton, MD, FRCP, FRCS

- consultant ophthalmic surgeon, Glaucoma Service, Moorfields Eye Hospital, London
- keith@keithbarton.co.uk
- financial disclosure: consultant to AqueSys

## MY EXPERIENCE WITH A TRABECULOTOME



### By Arsham Sheybani, MD

The Trab360 (SightSciences) is a trabeculotome, a nonpowered instrument for manually cutting the trabecular meshwork. I use the Trab360 in patients with angle recession, juvenile open-angle glaucoma, or pigment dispersion and for individuals seeking a purely internal option to enhance physiologic outflow (ie, not a bleb-forming procedure). Patients must be able to tolerate medications, which may be required to achieve lower IOP targets, since IOP reduction will ultimately be limited by episcleral venous pressure.

Here are a few tips based on my experience with the Trab360.

First, selecting and counseling patients are key. Do not expect dramatic IOP reductions if the distal outflow pathway is not working well (and you do not know that going in).

Second, the trabecular meshwork (TM) should be incised with the tip of the device. Sometimes, angling the tip upward will make incising the TM easier. I find it helps to cut an opening in the TM and then to back up just enough to allow for the cutting filament to enter Schlemm canal.

Third, the device has a limit to how much the wheel is dialed (Figure). The total excursion of the filament is about 180°. Once deployed, the filament is retracted back into the device and can be used one more time for a total of 360° of potential treatment. Each time the wheel is turned there are palpable “clicks.” Do not dial past a “click” unless you are sure you are in the canal, because the device unfortunately measures how much total excursion has occurred. It will not deploy more than about 360°.



(courtesy of SightSciences)

**Figure. The Trab360.**

Fourth, if performing this as a solo procedure, make the wound just anterior onto cornea.

Fifth, I received a referral for a patient with a small cleft and pupillary abnormality after the procedure. Slightly directing the tip upward as the filament advances can prevent iris root trauma.

### Arsham Sheybani, MD

- assistant professor, ophthalmology and visual sciences, Washington University School of Medicine in St. Louis, Missouri
- sheybaniar@vision.wustl.edu
- financial interest: none acknowledged

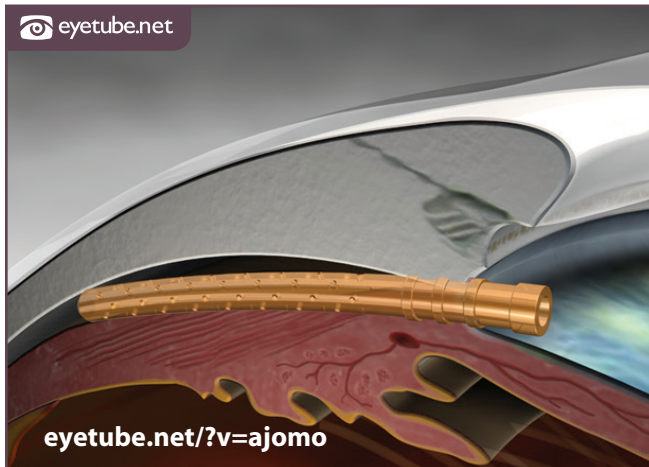


Figure 1. The CyPass Micro-Stent implanted.

secures the stent and allows aqueous to pass into Schlemm canal. The surgical technique is slightly easier for the iStent Inject than the iStent, because there is no sideways sliding of the former. Moreover, the iStent Inject has two stents pre-loaded, so surgeons can place both without exiting the eye.

The Hydrus (Ivantis) offers a dual-mechanism approach. This 8-mm flexible device is composed of nitinol. Like the iStent, the Hydrus has a snorkel that allows aqueous to flow into Schlemm canal. The length of the device allows it to dilate and support Schlemm canal for approximately 3 clock hours. The dilation of the canal is thought to allow greater flow of aqueous through the trabecular meshwork, because it places the trabecular meshwork on tension. The collector channels are segmented, and the Hydrus disrupts the tissue bridges, allowing aqueous to flow through the device and access more collector channels. Enrollment is complete in the Hydrus IV pivotal trial. (For more on this trial and the Hydrus, visit [eyetube.net/?v=iluli](http://eyetube.net/?v=iluli).)

The design of the Kahook Dual Blade (New World Medical) is somewhat similar to that of the Trabectome, but the former uses actual blades instead of electrocautery. The tapered tip of the Kahook Dual Blade is designed to ease the instrument's entry into Schlemm canal, after which the device slides along the trabecular meshwork. The blade that is in the canal lifts and stretches the trabecular meshwork so that the second blade can safely cut the tissue. This allows for cleaner tissue removal and minimizes damage to adjacent tissue.<sup>2</sup>

### Suprachoroidal Space

The CyPass Micro-Stent (Transcend Medical) is made of a polyimide material. The device is a tube that is 6 mm long and has an inner diameter of 300  $\mu\text{m}$  that allows aqueous to flow from the anterior chamber to the suprachoroidal space. The surgeon places the stent under gonioscopy, with the target located between the scleral spur

## MY EXPERIENCE WITH A DUAL-BLADE DEVICE



**By Leonard K. Seibold, MD**

The Kahook Dual Blade (New World Medical) is a simple yet elegant device designed to reduce IOP through the removal of a section of trabecular meshwork (TM) and the inner wall of Schlemm canal. Under direct gonioscopic visualization, the dual blade is inserted through a clear corneal incision and advanced to the opposite angle. The sharp tip of the device is used to pierce the TM and enter the canal. As the instrument advances in the canal, the ramp of the device gently elevates the TM toward the dual blades on either side of the device where it is incised. The result is a nearly complete excision of the TM from an ab interno approach.

The procedure of incising TM to increase aqueous outflow has long been established as a means of reducing IOP in glaucoma. Long-term success in adults with the disease has been limited, however, in part due to the residual TM leaflets that can scar closed postoperatively. The novelty of the Kahook Dual Blade resides in its ability to more completely remove TM, which one hopes will achieve better long-term outcomes. In cadaver eyes, my colleagues and I have shown that TM excision with the dual blade is more complete than with the Trabectome (NeoMedix) or a microvitrectomy retinal blade.<sup>1</sup>

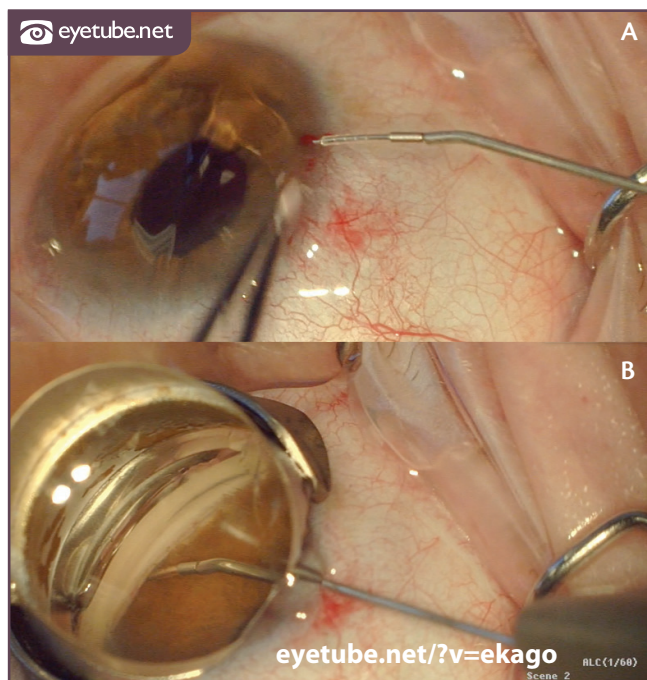
My initial experience with the device has been positive. The procedure itself is relatively straightforward and quick to perform. It can be a stand-alone procedure or performed in combination with cataract surgery. I have achieved excellent IOP outcomes thus far, especially when I have combined the Kahook Dual Blade with endoscopic cyclophotocoagulation, which targets aqueous production in addition to outflow without leaving an implant behind. In patients with peripheral anterior synechiae, I have used the dual blade not only to perform goniosynechiolysis but also subsequent TM removal. The most common postoperative complication is hyphema, which is typically mild and to be expected after most forms of goniotomy or trabeculotomy.

Long-term data on efficacy and safety are needed to better determine where this device fits in the glaucoma surgeon's armamentarium.

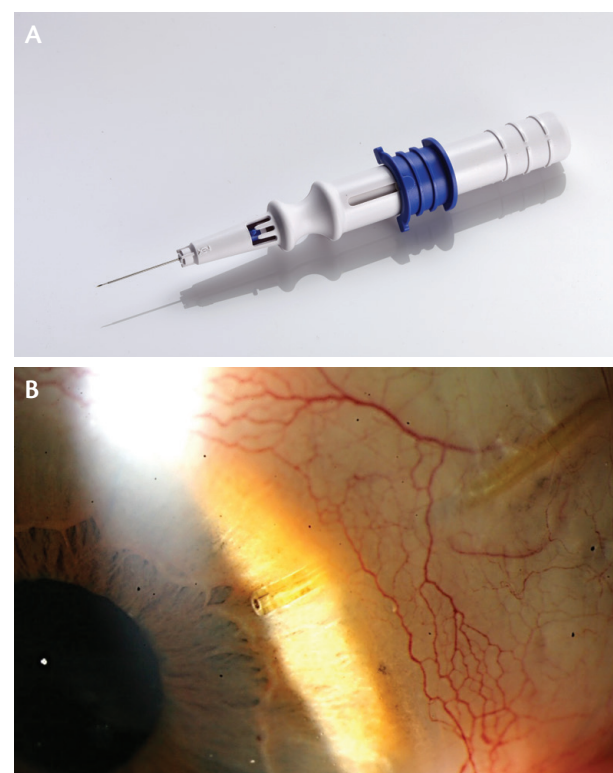
1. Seibold LK, Soohoo JR, Ammar DA, Kahook MY. Preclinical investigation of ab interno trabeculotomy using a novel dual-blade device. *Am J Ophthalmol*. 2013;155(3):524-529.

**Leonard K. Seibold, MD**

- assistant professor of ophthalmology, University of Colorado School of Medicine, Aurora
- leonard.seibold@ucdenver.edu
- financial disclosure: consultant to New World Medical



**Figure 2.** The iStent Supra attached to the inserter prior to entry into the eye (A) and after full insertion into the suprachoroidal space (B).



**Figure 3.** The Xen45 is implanted via a 27-gauge needle (A). View of the shunt at the slit lamp (B).

and the ciliary body. The stent then enters the potential space between the inner scleral wall and the ciliary body and choroid (Figure 1). Transcend Medical announced completion of the Compass pivotal trial evaluating the CyPass Micro-Stent, and the company expects to file a pre-market approval application with the FDA in the second half of this year.

Like the CyPass, the iStent Supra (Glaukos) targets the uveoscleral outflow pathway (Figure 2). A US investigational device exemption trial of the stent is underway.

#### Subconjunctiva

The Xen45 (AqueSys) is a soft, tubular implant composed of porcine gelatin that is cross-linked with glutaraldehyde. The device is 6 mm long and has three different lumen sizes of 45, 63, and 140  $\mu\text{m}$ . The flexible shunt is located within a 27-gauge needle, which is passed through the anterior trabecular meshwork and sclera but under the conjunctiva, allowing the tubular structure to deliver aqueous from the anterior chamber to the subconjunctival space (Figure 3). A bleb then forms, without any external cutting or suturing. Despite the formation of a bleb, the Xen45 still seems to fit the definition of MIGS. The US investigational device exemption trial of the Xen45 is fully

enrolled. Allergan recently announced that it will acquire AqueSys and that it expects final FDA approval of the technology via the 510(k) device pathway in 2016 or early 2017.

With multiple devices addressing various mechanisms on the way, the outlook for MIGS is promising. ■

1. Saheb H, Ahmed IK. Micro-invasive glaucoma surgery: current perspectives and future directions. *Curr Opin Ophthalmol*. 2012;23(2):96-104.
2. Seibold LK, Soohoo JR, Ammar DA, Kahook MY. Preclinical investigation of ab interno trabeculectomy using a novel dual-blade device. *Am J Ophthalmol*. 2013;155(3):524-529.

#### Michael Greenwood, MD

- fellow, glaucoma, cornea, cataract, and refractive surgery, Vance Thompson Vision, Sioux Falls, South Dakota
- (605) 361-3937; migreenw@gmail.com; Twitter: @migreenw
- financial interest: none acknowledged

#### John Berdahl, MD

- clinician and researcher, Vance Thompson Vision, Sioux Falls, South Dakota
- (605) 361-3937; john.berdahl@vancethompsonvision.com
- financial disclosure: consultant to Glaukos

## Come See The Most Advanced Specular Microscope On The Market Today

### EM-4000

- Dark Area Analysis
- Fully Automatic Acquisition & Capture
- Touch-Screen Operation
- Built-In Database

Visit us at AAO Booth #1435!



888-449-4045 • WWW.TOMEYUSA.COM

